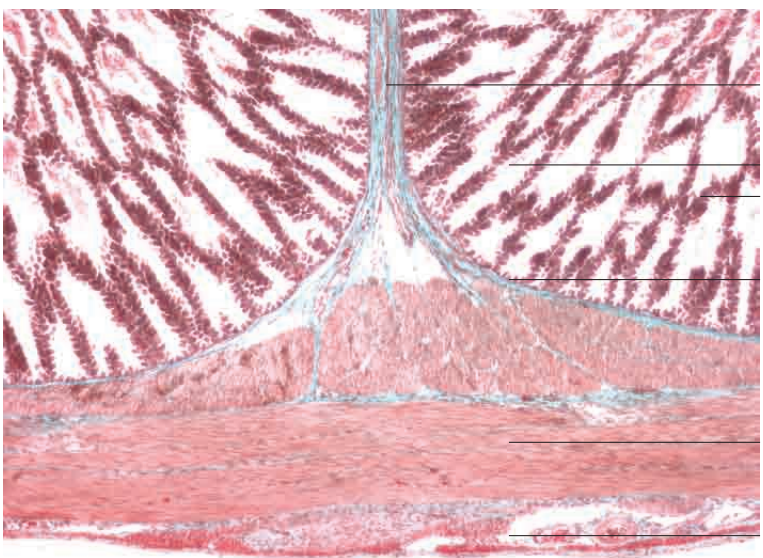
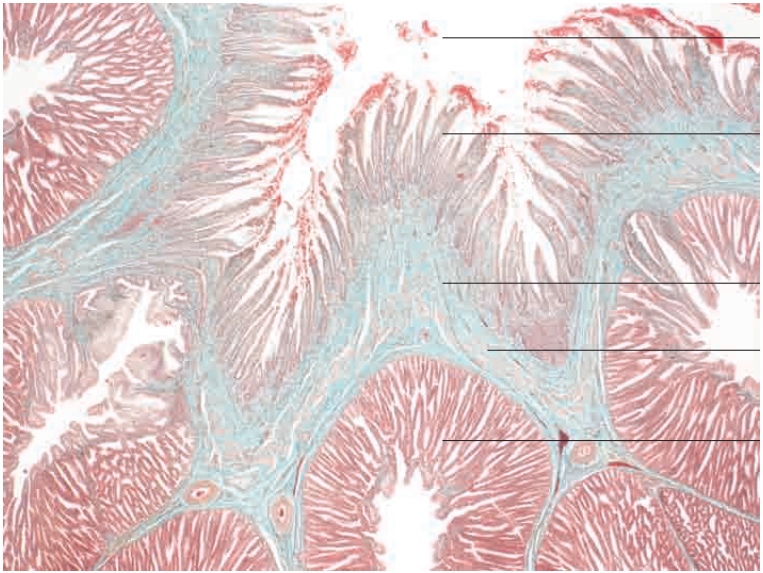
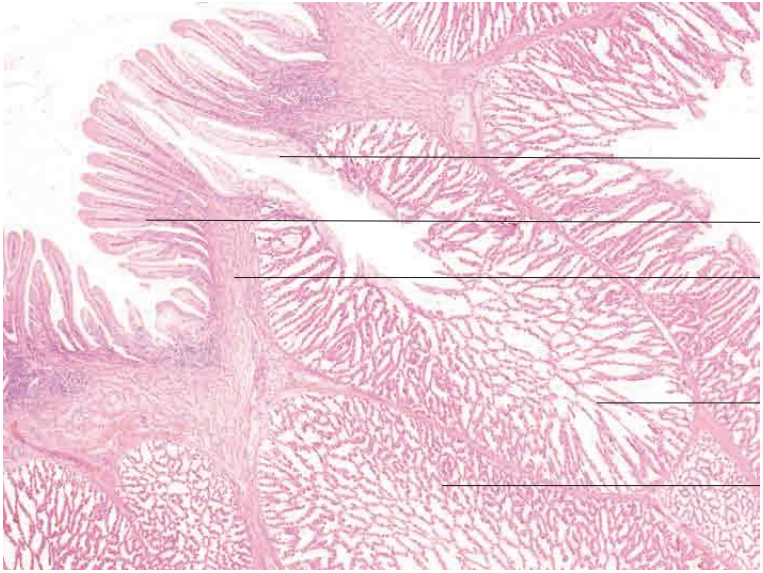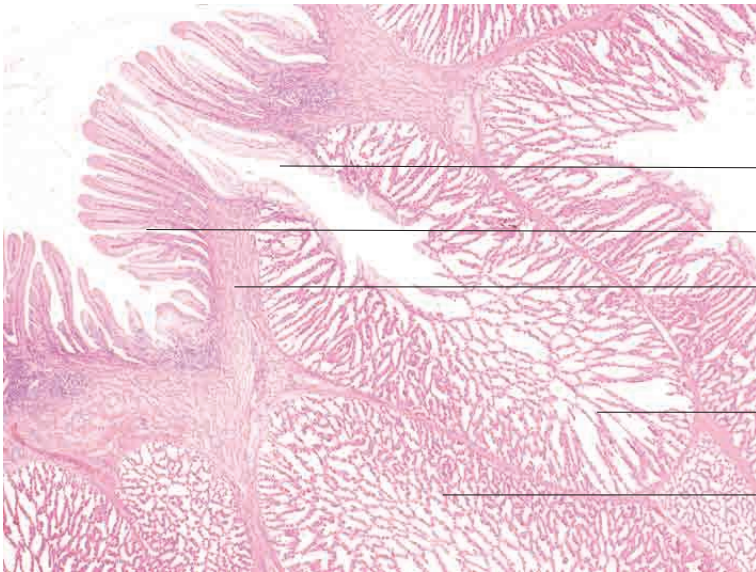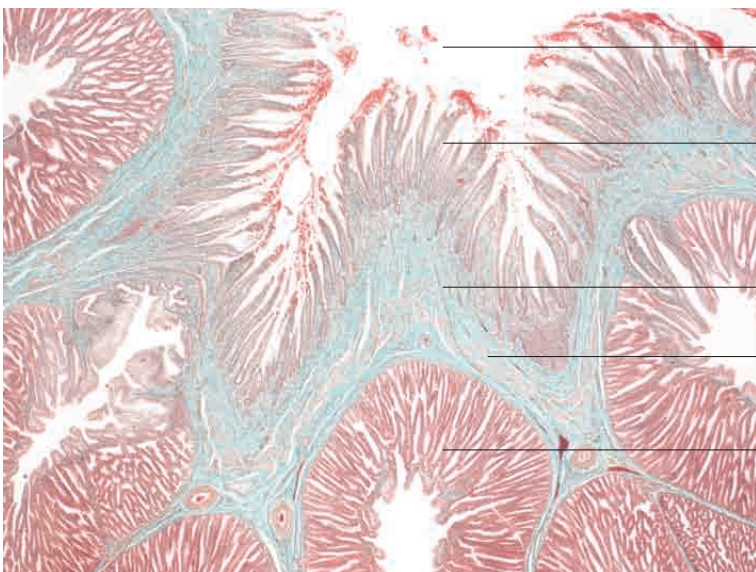


10 Digestive system

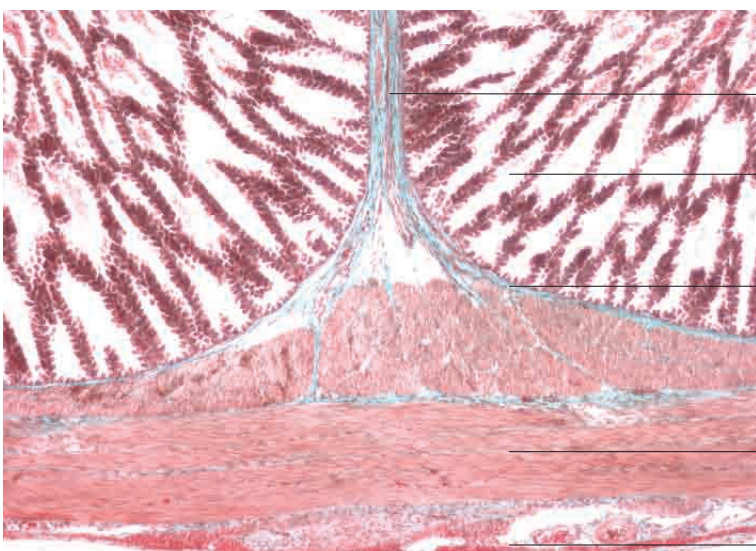




- _____ Lumen of deep gastric gland
- _____ Superficial gastric glands
- _____ Lamina propria mucosae
- _____ Deep gastric glands
- _____ Deep gastric glands (flat section)
- Glandular stomach, chicken. H.E. stain; x40.

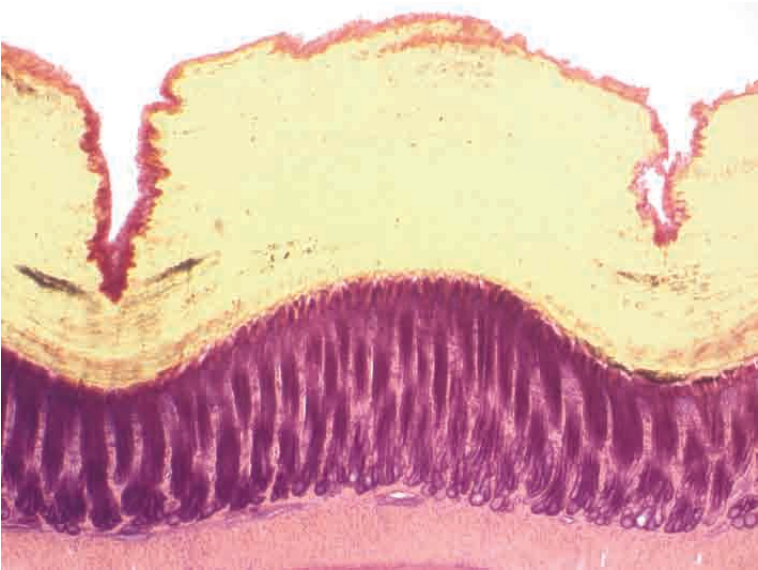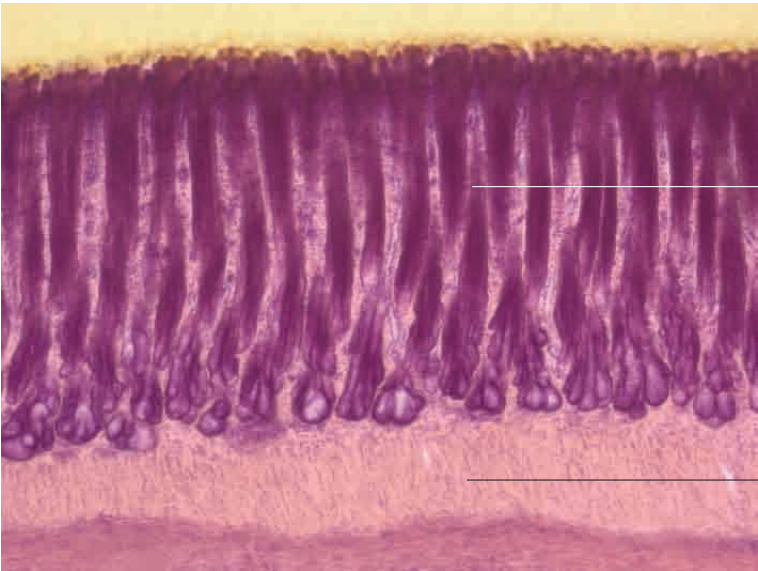
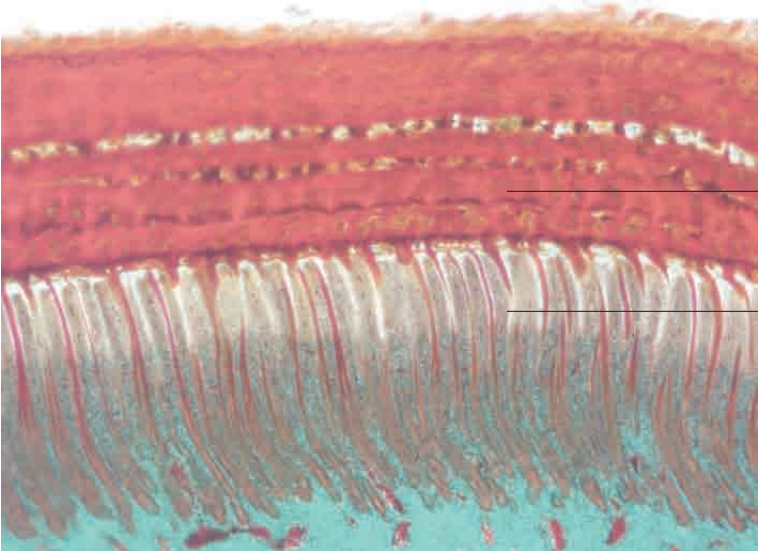


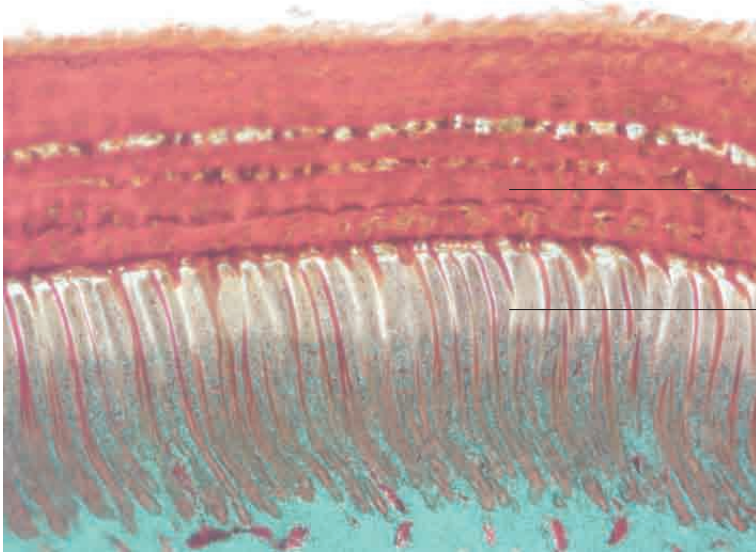
- _____ Lumen of glandular stomach
- _____ Superficial gastric glands
- _____ Lamina propria mucosae
- _____ Lamina muscularis mucosae
- _____ Deep gastric glands
- Glandular stomach, chicken. Goldner's Masson trichrome stain; x40.



- _____ Lamina propria mucosae with smooth muscle
- _____ Deep gastric glands with simple cuboidal to columnar epithelium
- _____ Lamina propria mucosae
- _____ Tunica muscularis
- Glandular stomach, chicken. Goldner's Masson trichrome stain; x80.

10 Digestive system

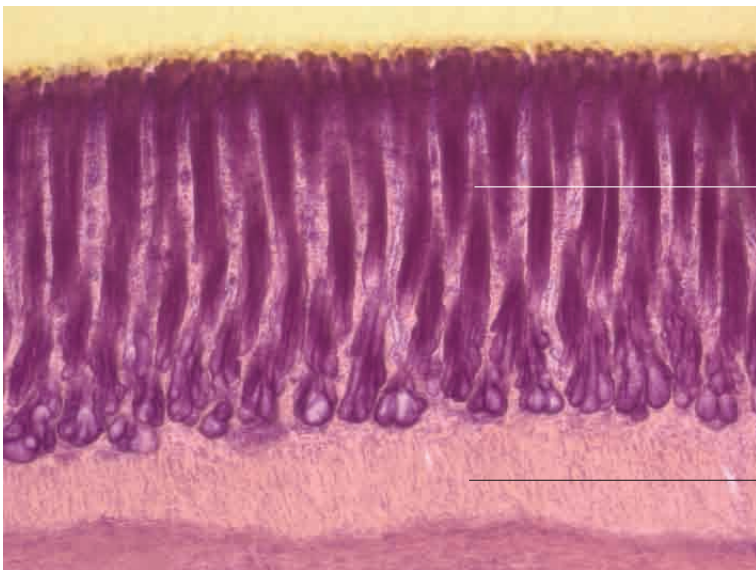




Koilin layer

Tubular gastric glands

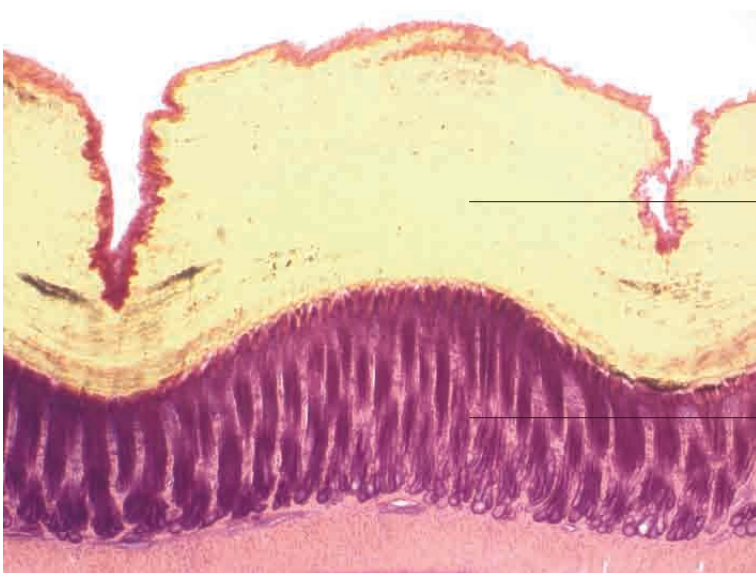
Muscular stomach, crane. Goldner's Masson trichrome stain; x40.



Tubular gastric glands

Tunica muscularis

Muscular stomach, chicken. H.E. stain; x100.



Cuticle

Tubular glands with columnae verticales

Muscular stomach, chicken. H.E. stain; x40.