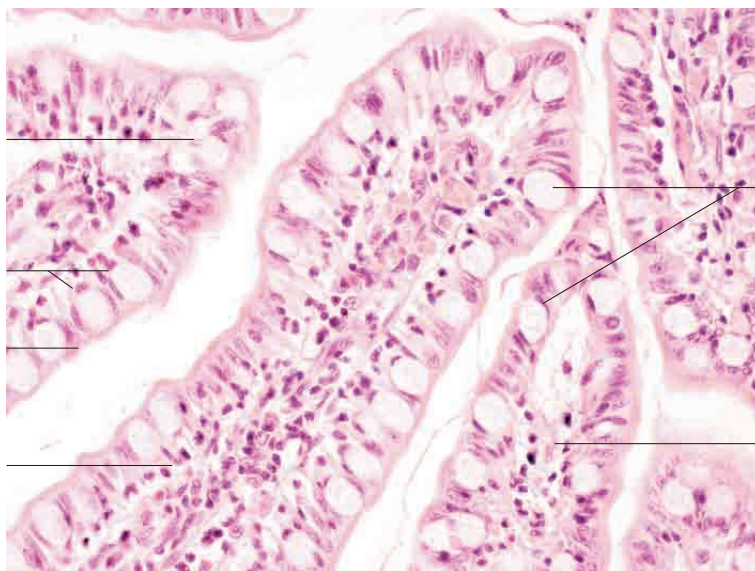
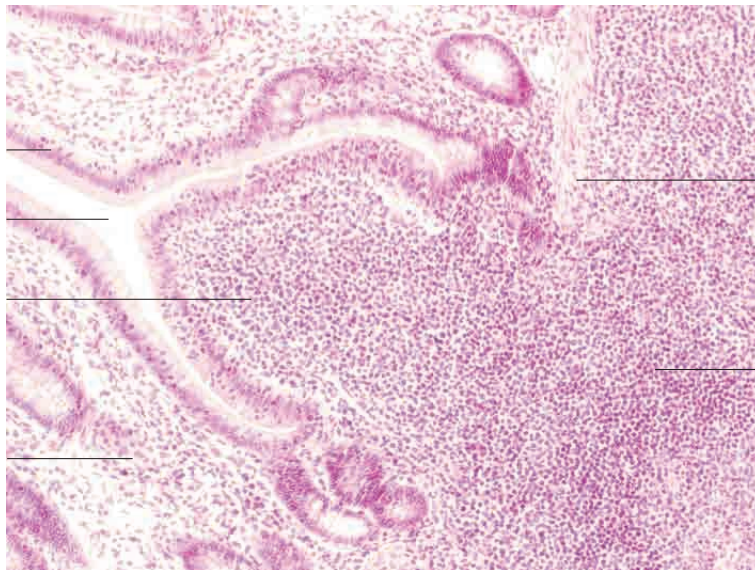
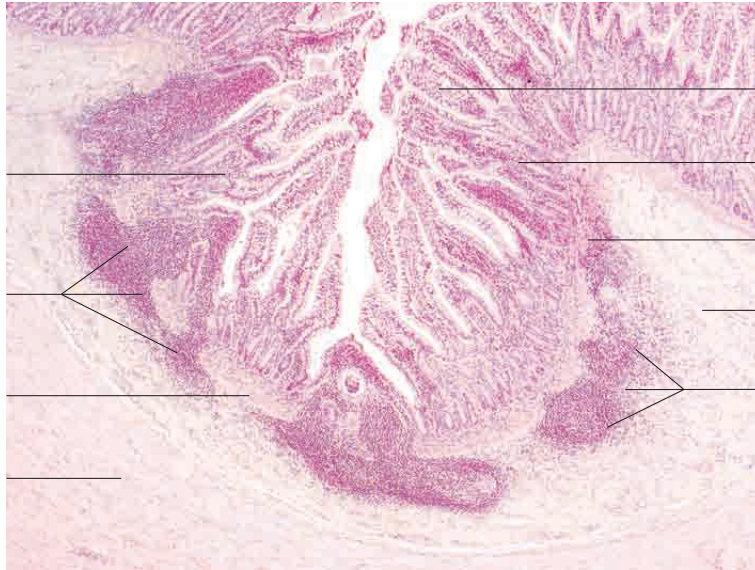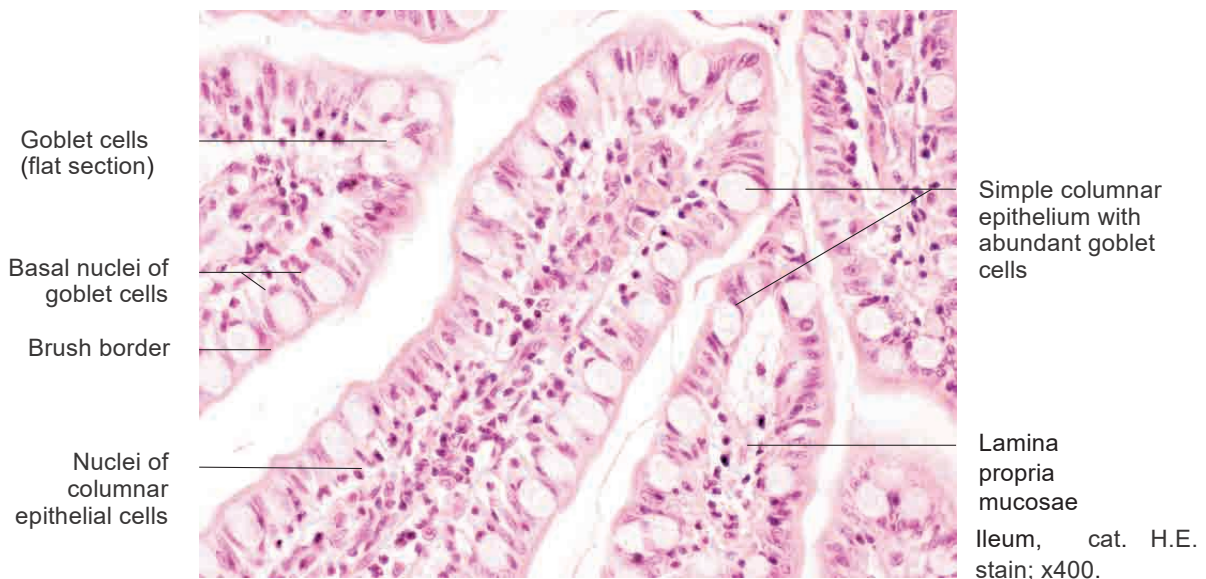
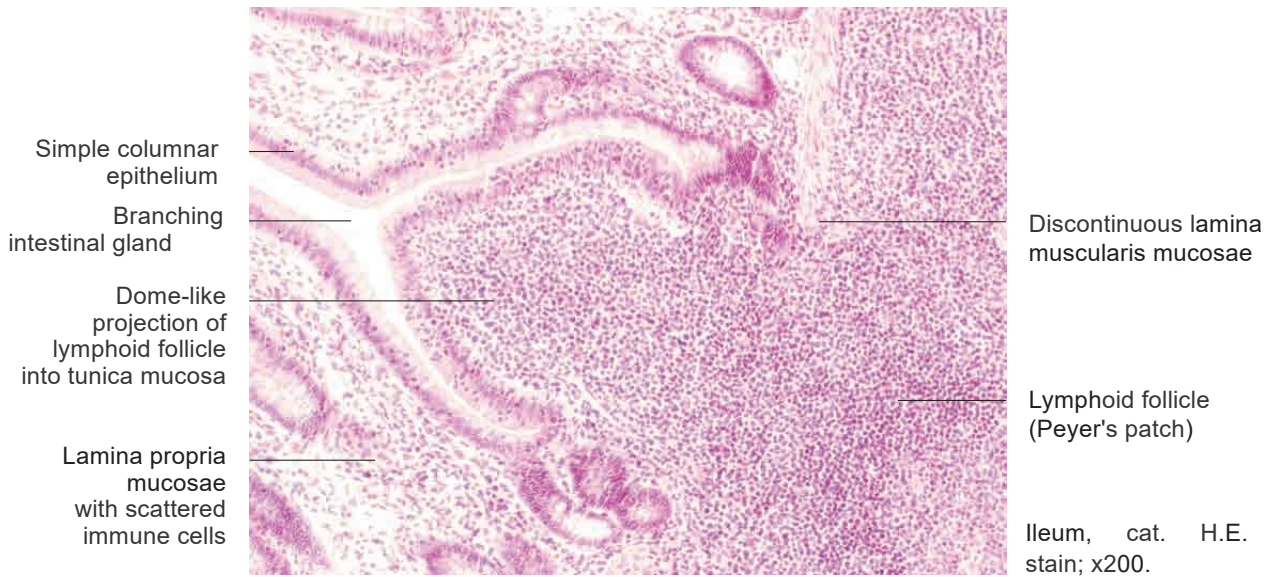

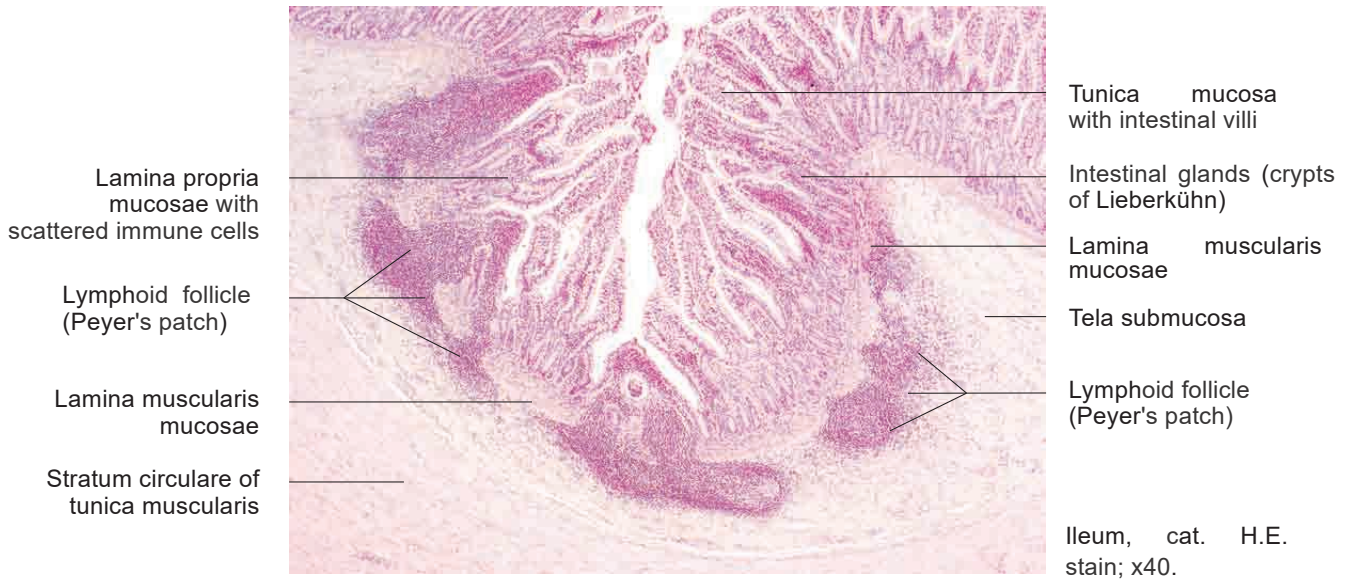
# 10 Digestive system

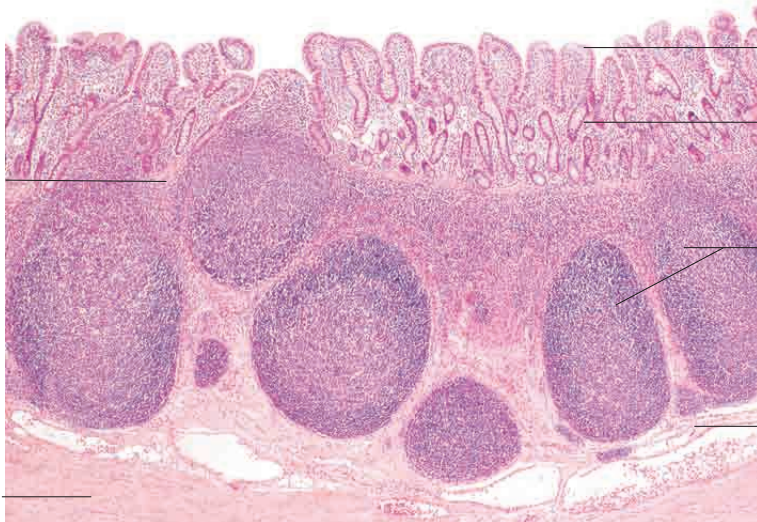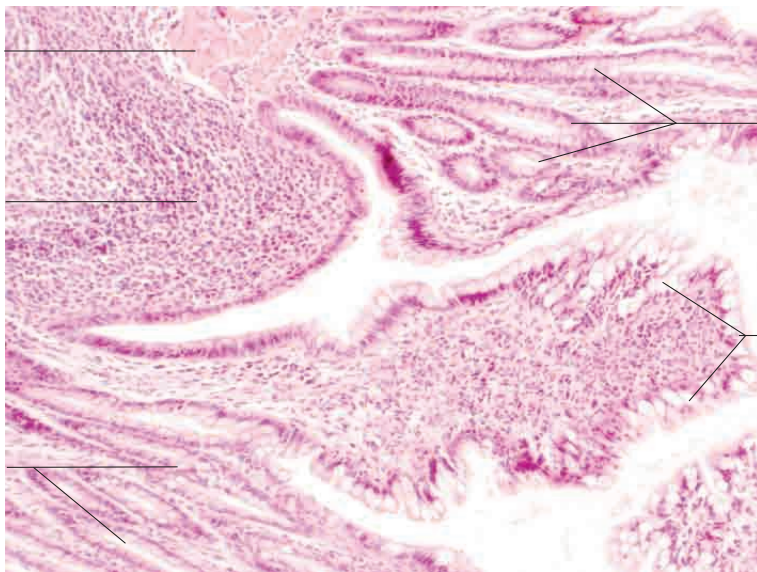
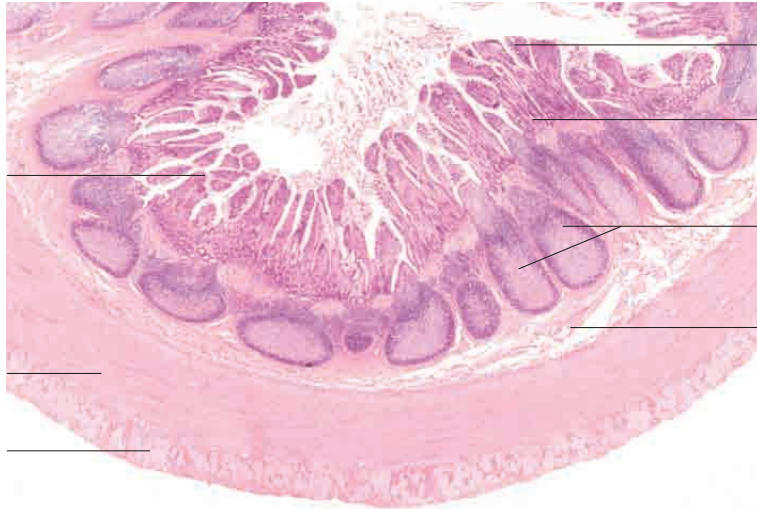---

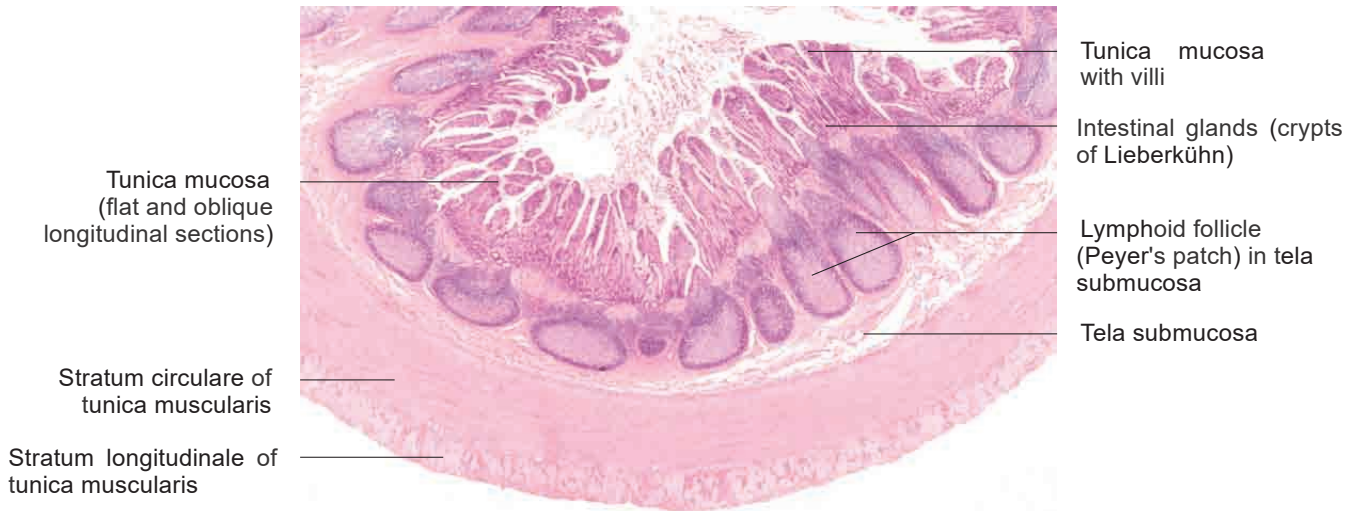



# 10 Digestive system

---

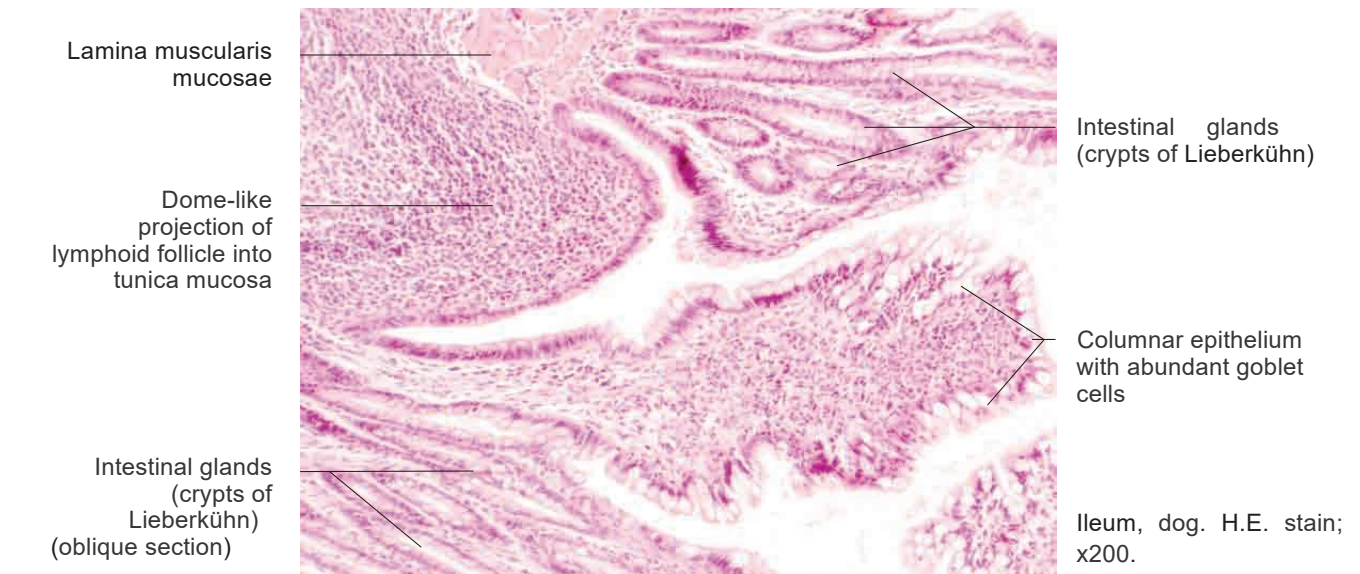




Tunica mucosa with villi  
 Intestinal glands (crypts of Lieberkühn)  
 Lymphoid follicle (Peyer's patch) in tela submucosa  
 Tela submucosa

Tunica mucosa (flat and oblique longitudinal sections)  
 Stratum circulare of tunica muscularis  
 Stratum longitudinale of tunica muscularis

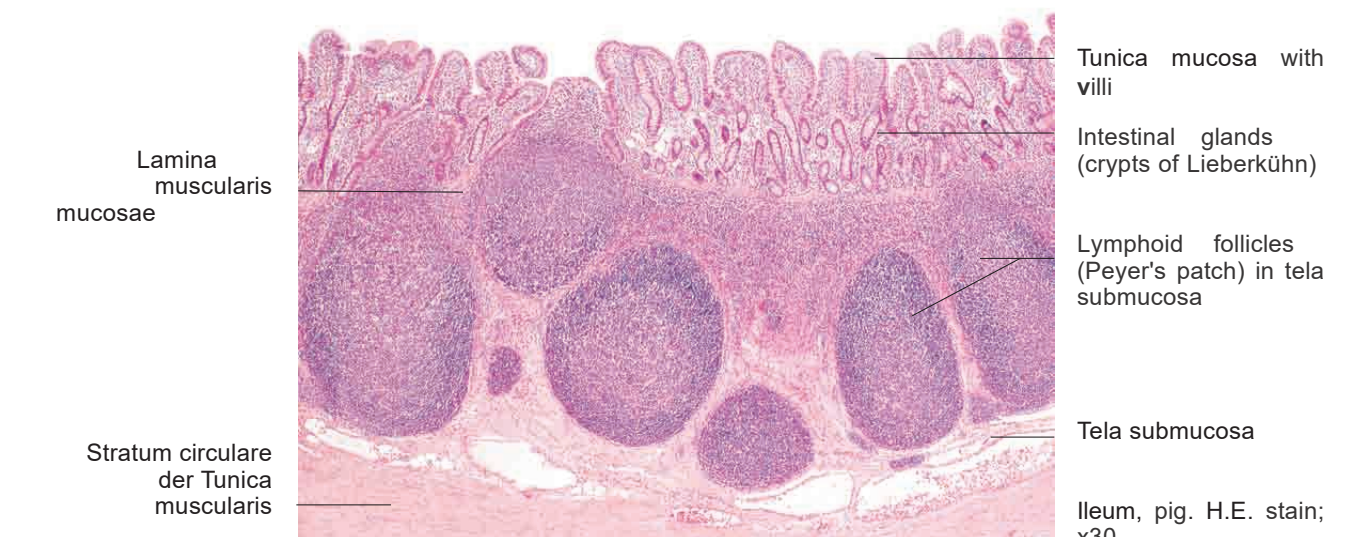Ileum, dog. H.E. stain; x7.



Intestinal glands (crypts of Lieberkühn)  
 Columnar epithelium with abundant goblet cells

Lamina muscularis mucosae  
 Dome-like projection of lymphoid follicle into tunica mucosa  
 Intestinal glands (crypts of Lieberkühn) (oblique section)

Ileum, dog. H.E. stain; x200.



Tunica mucosa with villi  
 Intestinal glands (crypts of Lieberkühn)  
 Lymphoid follicles (Peyer's patch) in tela submucosa  
 Tela submucosa

Lamina muscularis mucosae  
 Stratum circulare der Tunica muscularis

Ileum, pig. H.E. stain; x30.

10 Digestive system

---

