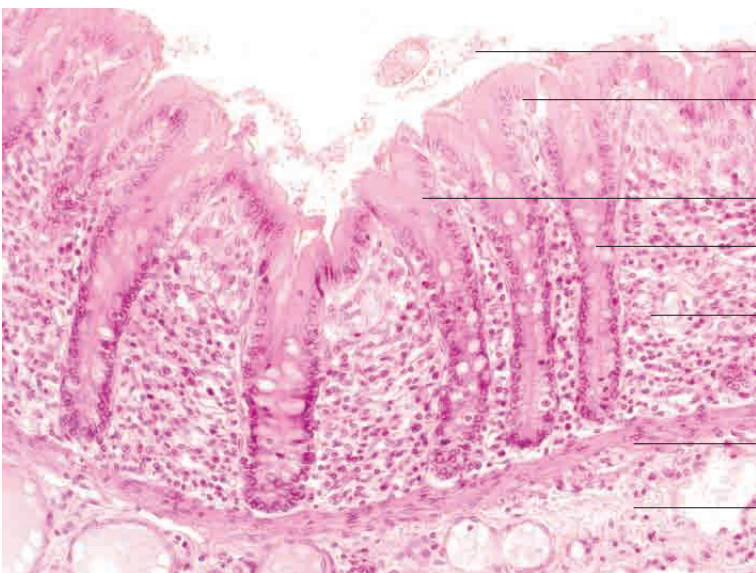
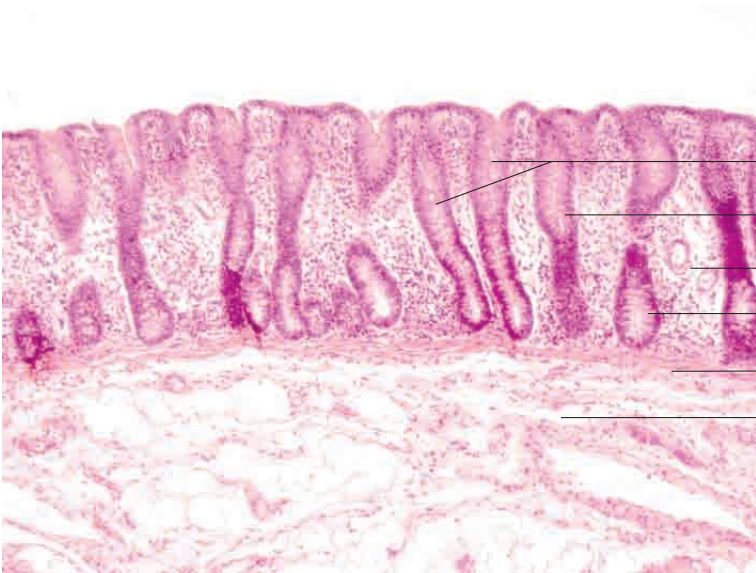
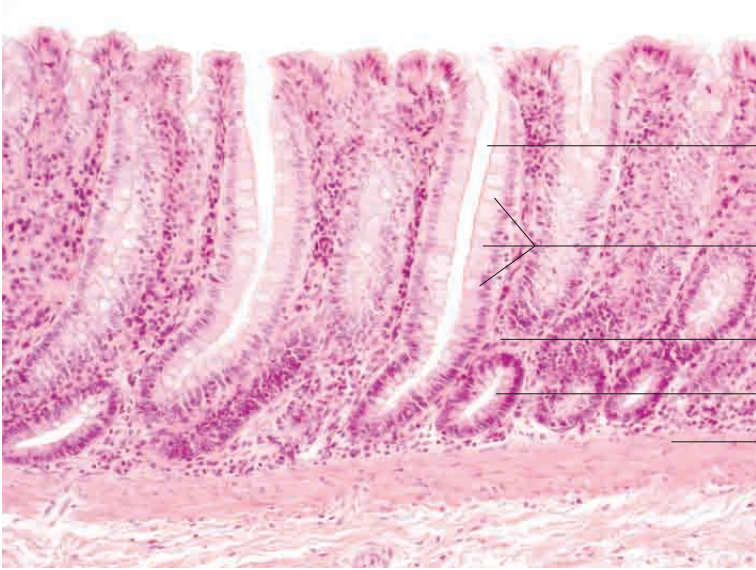
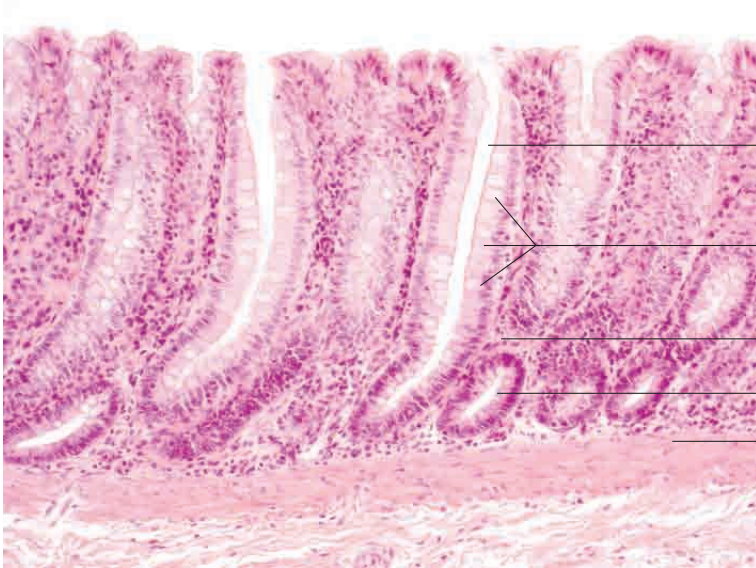


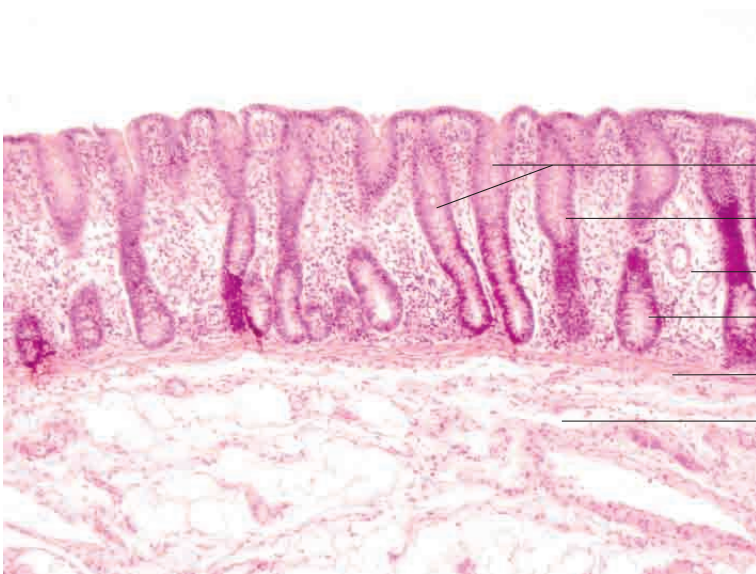
10 Digestive system





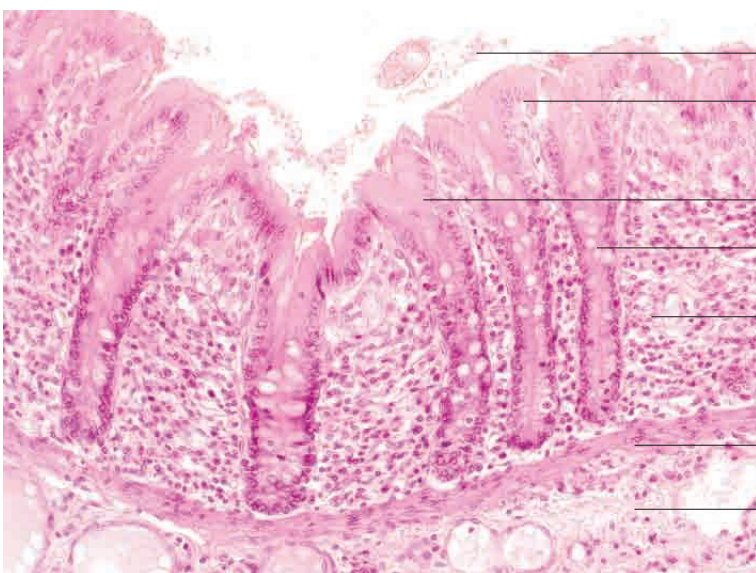
- Intestinal gland (crypt of Lieberkühn)
- Simple columnar epithelium with abundant goblet cells
- Lamina propria mucosae
- Simple tubular glands
- Lamina muscularis mucosae

Caecum, dog. H.E. stain; x200.



- Intestinal glands (crypts of Lieberkühn)
- Simple columnar epithelium
- Lamina propria mucosae
- Simple tubular glands
- Lamina muscularis mucosae
- Tela submucosa

Caecum, pig. H.E. stain; x100.



- Mucus and cell fragments
- Desquamating epithelial cells
- Cytoplasm of epithelial cells (flat section)
- simple tubular glands
- Lamina propria mucosae
- Lamina muscularis mucosae
- Tela submucosa

Caecum, horse. H.E. stain; x200.

